MRI TUYẾN YÊN

BS. Cao Thiên Tượng

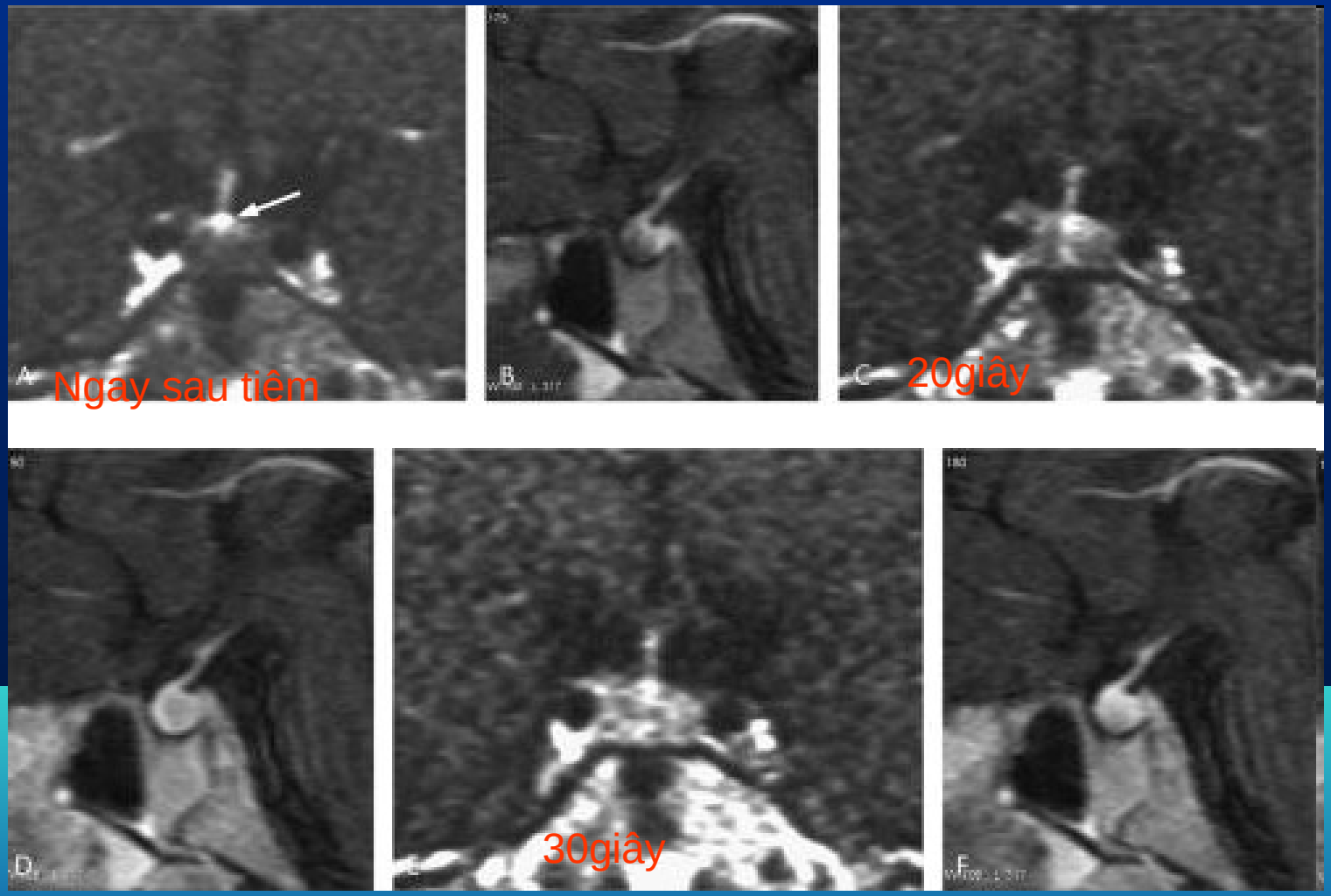
A
Ngay sau tiêm
B
C
20giây
D
30giây
F

Nang trong yên

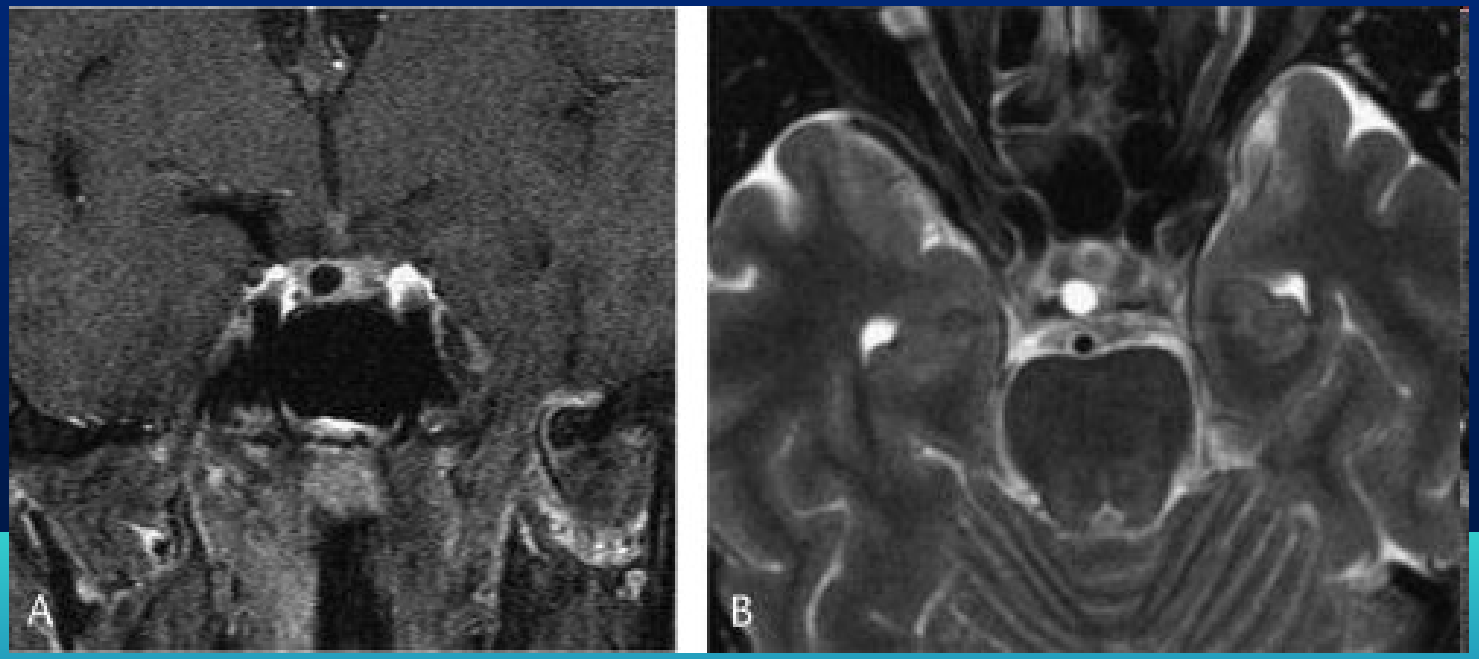

“Định luật ngón cái”

- Ở những người có nội tiết bình thường, tổn thương tuyến yên < 2mm, gần như luôn luôn là phát hiện tình cờ và không quan trọng.

Nang tuyến yên

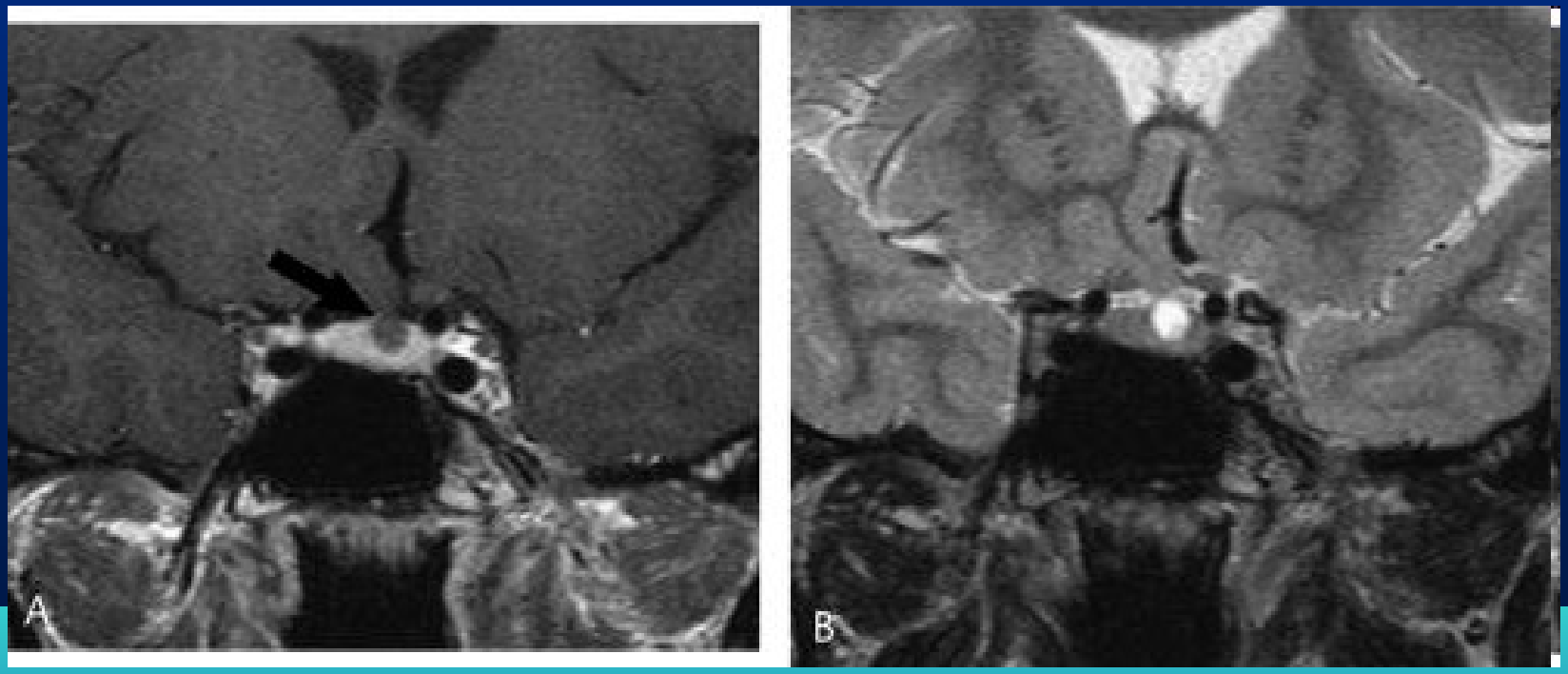

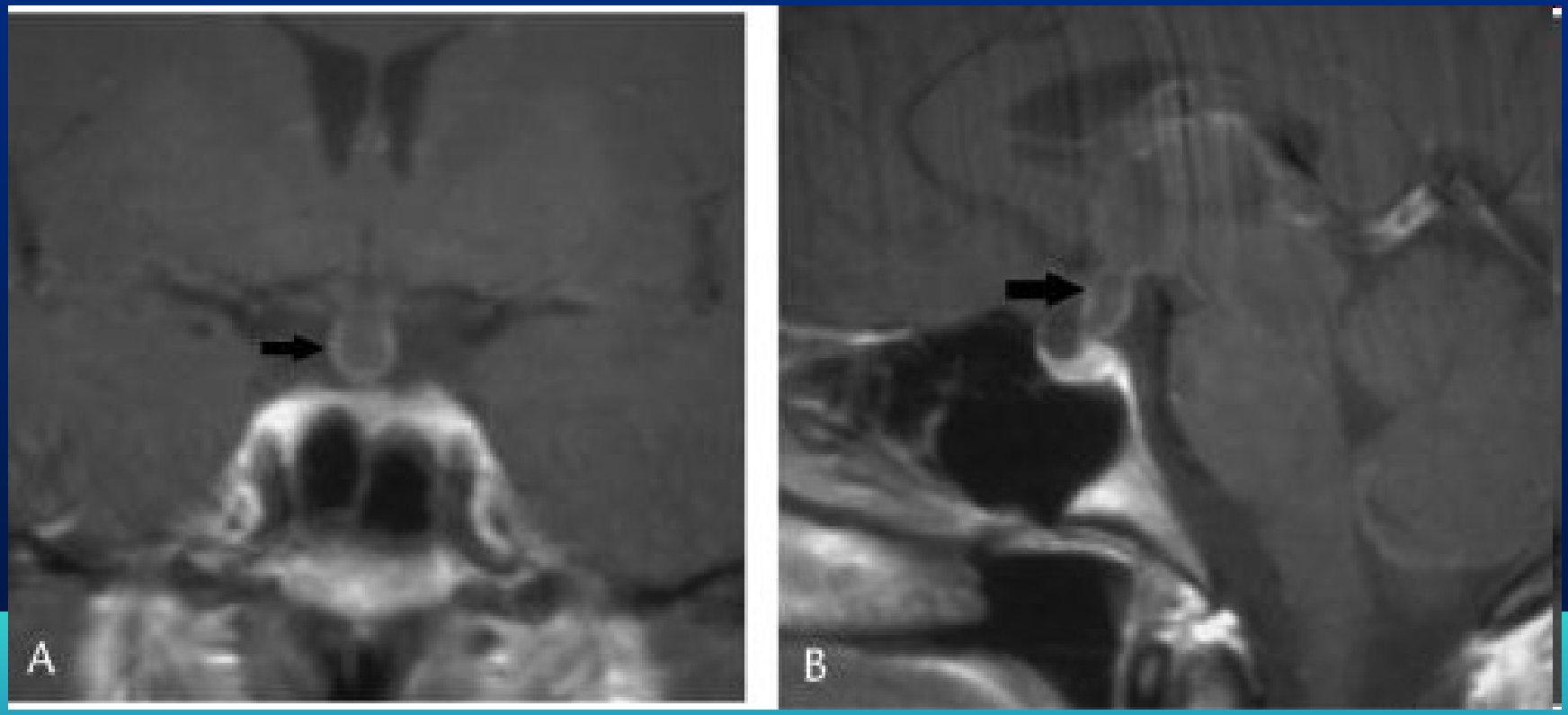
A
B

Đóng vôi tuyến yên

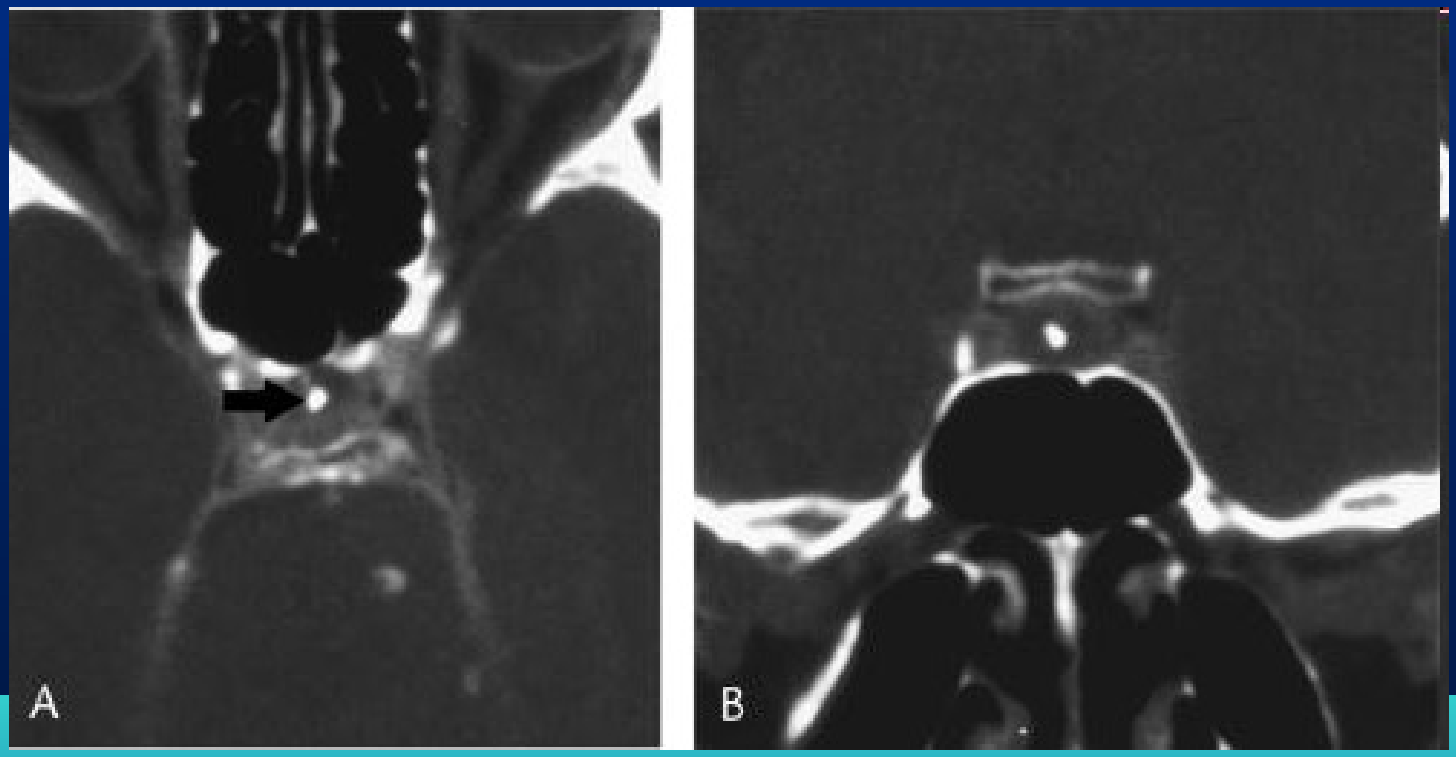

Gai xương yên

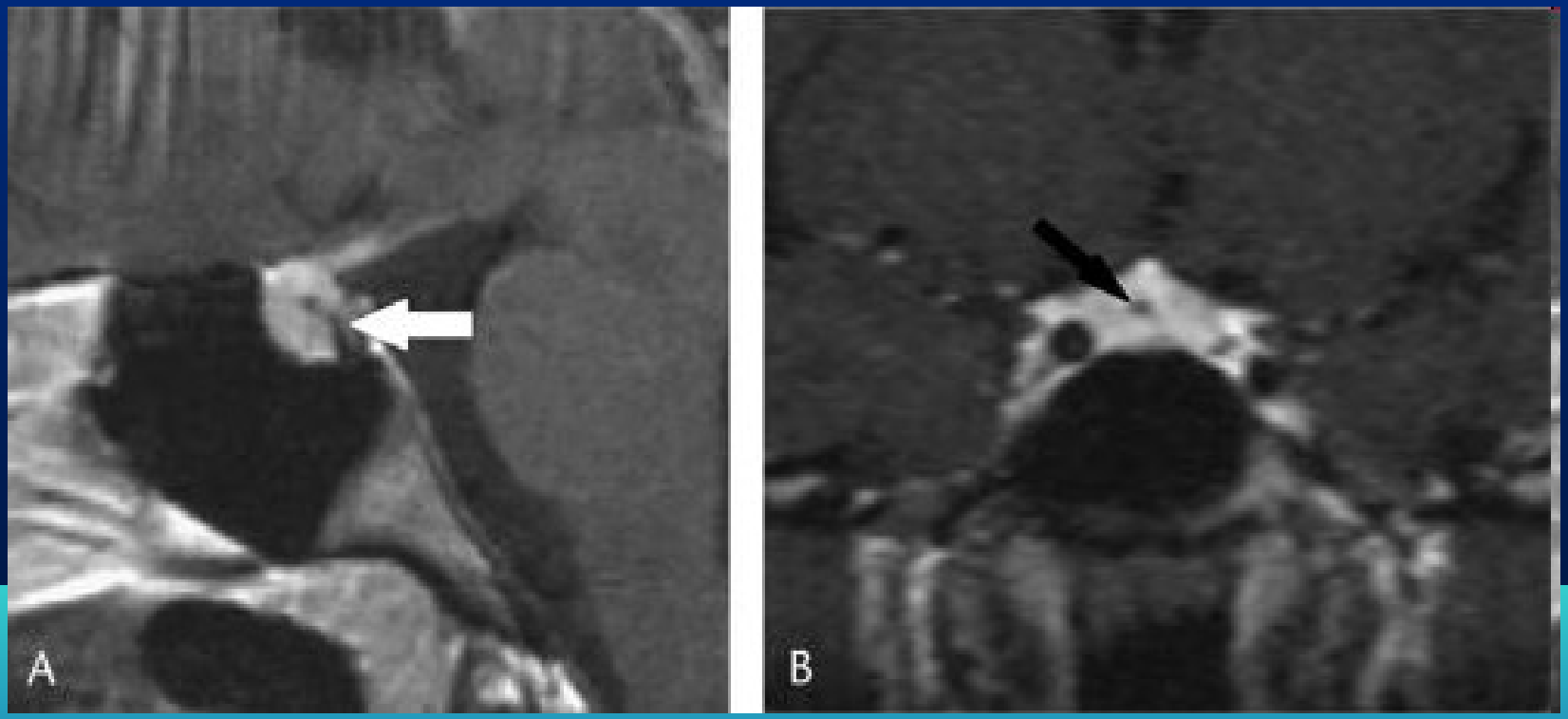

Kissing động mạch cảnh trong

Hố yên trống

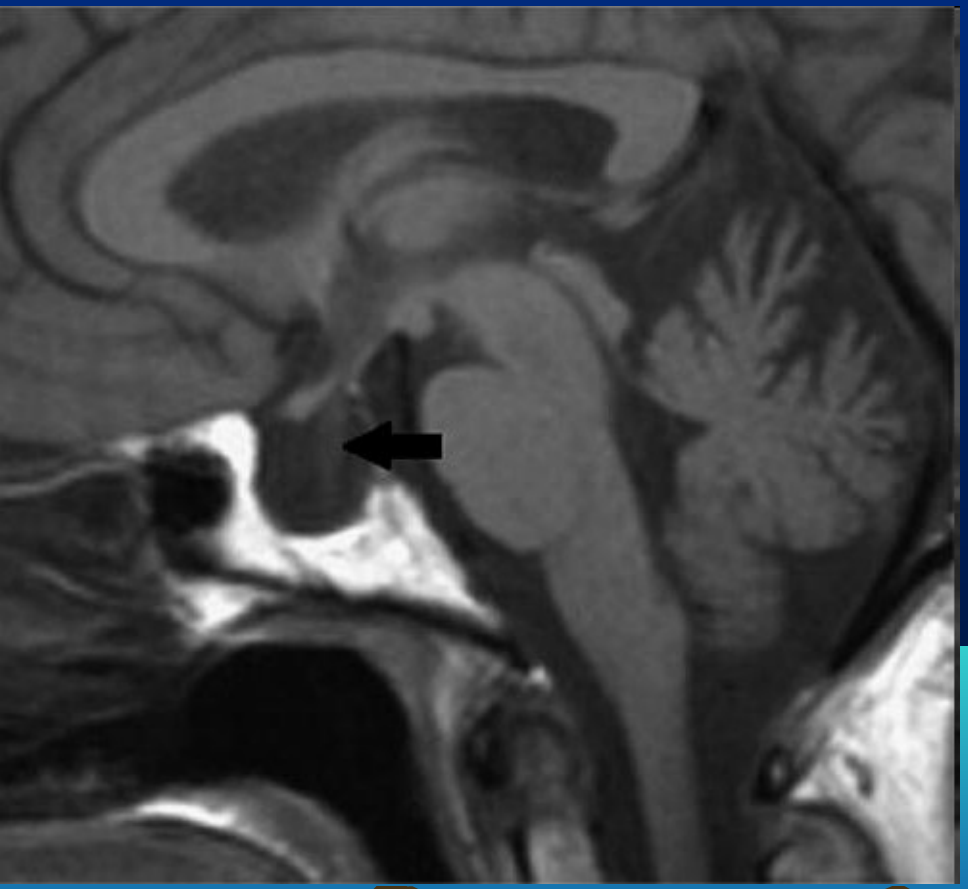

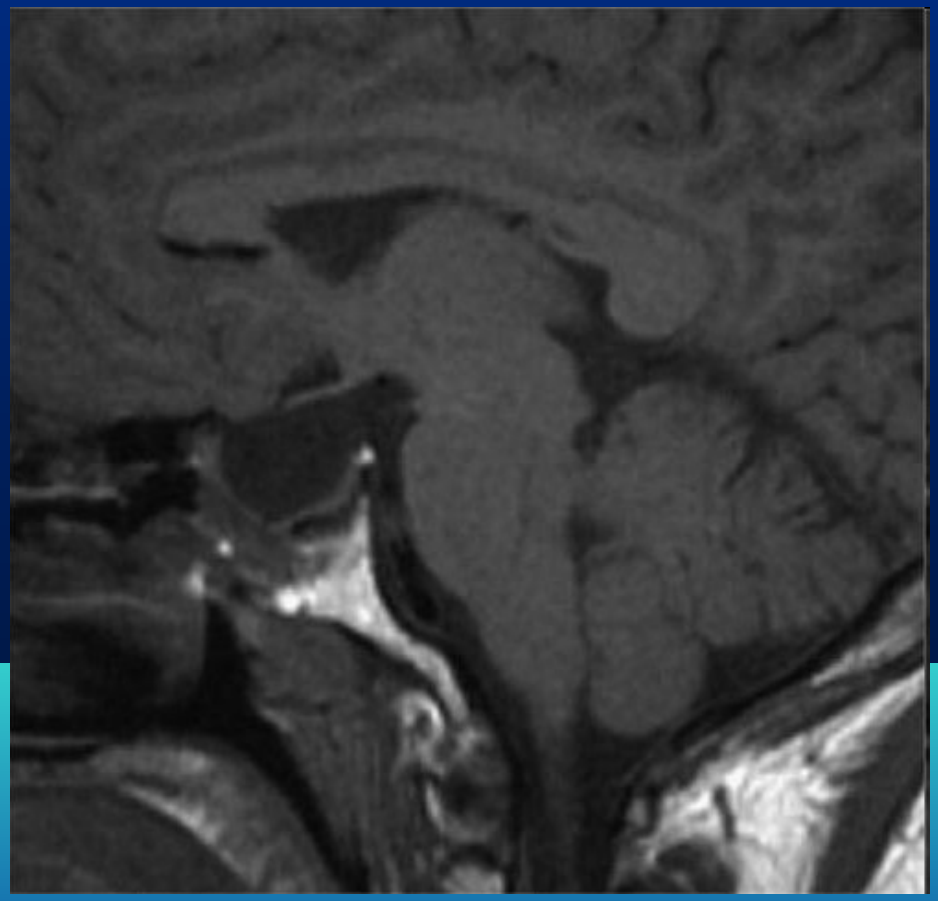

Tăng sản tuyến yên

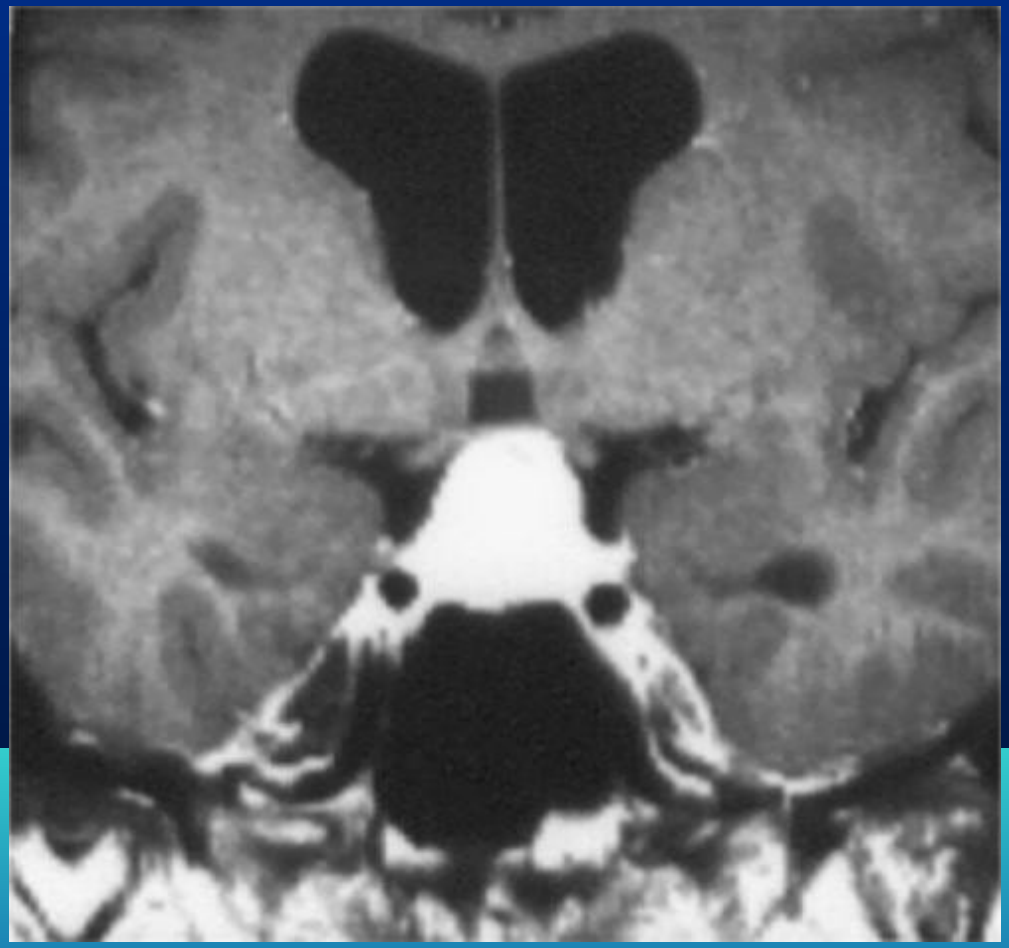

U tuyến yên kích thước nhỏ

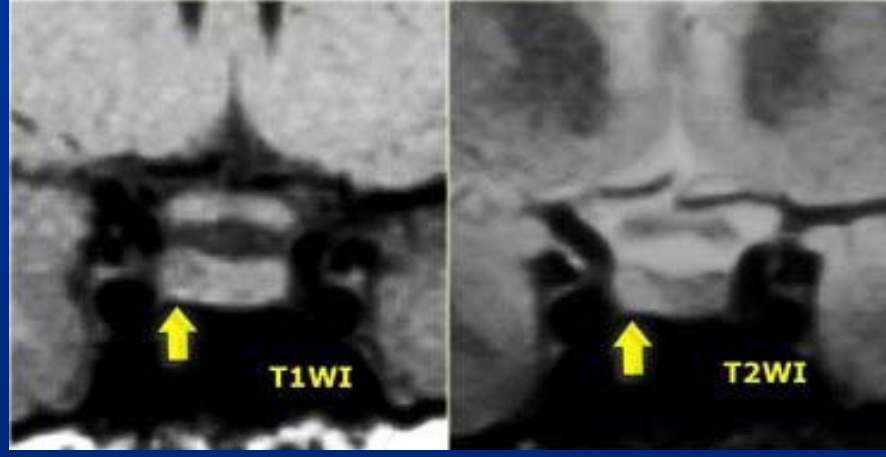

- Kích thước dưới 10mm
- Điển hình: giảm tín hiệu trên T1W, tăng tín hiệu trên T2W

U tuyến yên kích thước nhỏ

- 75-80% u tuyến yên tiết hormon
- U tuyến yên tiết prolactin thường gặp nhất. LS: Vô kinh và tiết sữa.

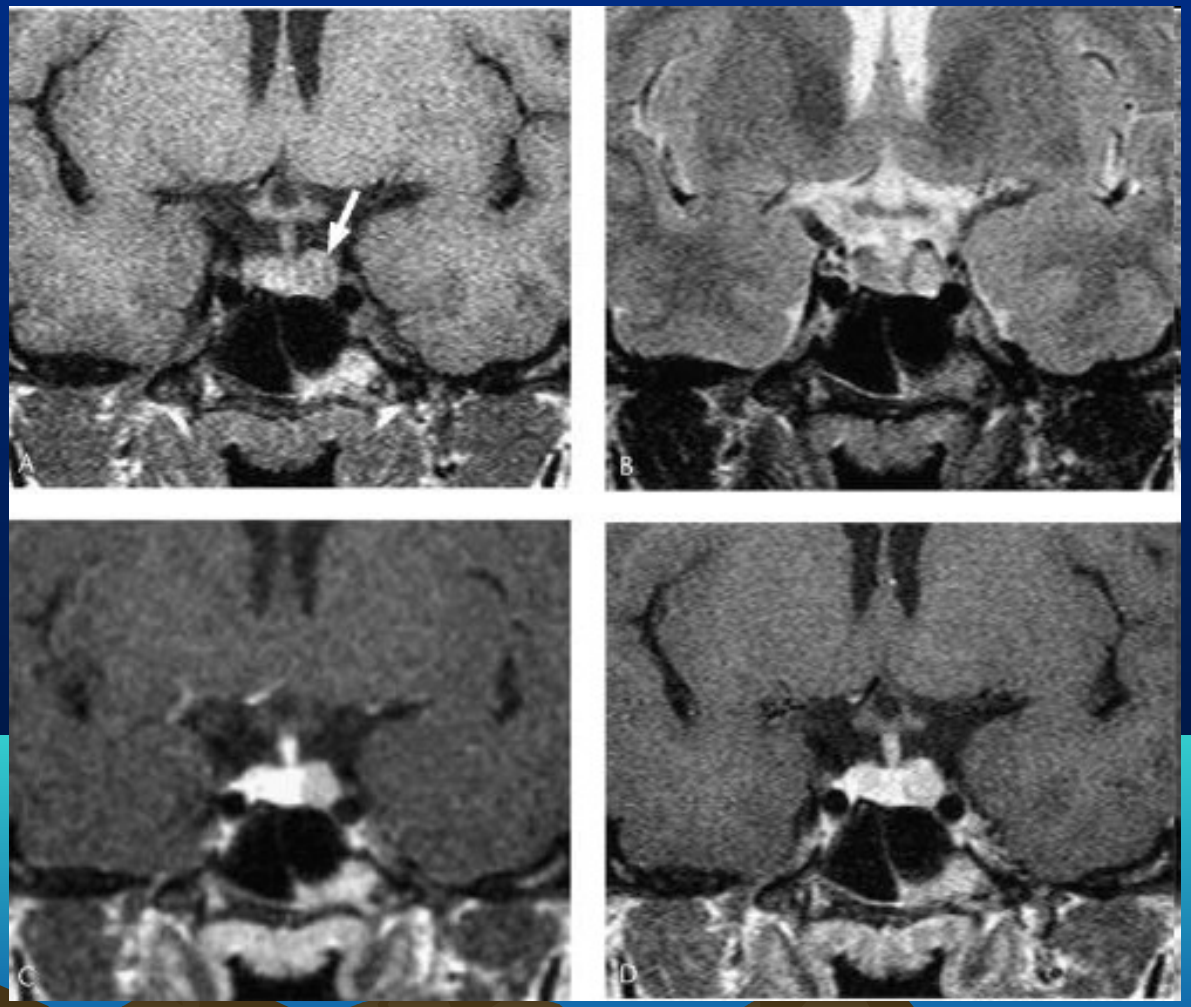
A
B
C
D

Microadenoma hình ảnh

- T1W trước tiêm: vùng tín hiệu thấp hình tròn, oval, dẹt, tam giác [75%]
- Một số u tăng tín hiệu trên T1W [xuất huyết].
- Tăng tín hiệu trên T2W [80%]
- U tiết GH giảm hoặc đồng tín hiệu trên T2W.
- 5-10% chỉ phát hiện được trên hình sau tiêm Gd.
- Dynamic tuyến yên tăng độ nhạy thêm 10%

Microadenoma hình ảnh

- Lồi bờ, hoành yên khu trú
- Lệch cuống tuyến yên

Giảm tín hiệu trên T1W

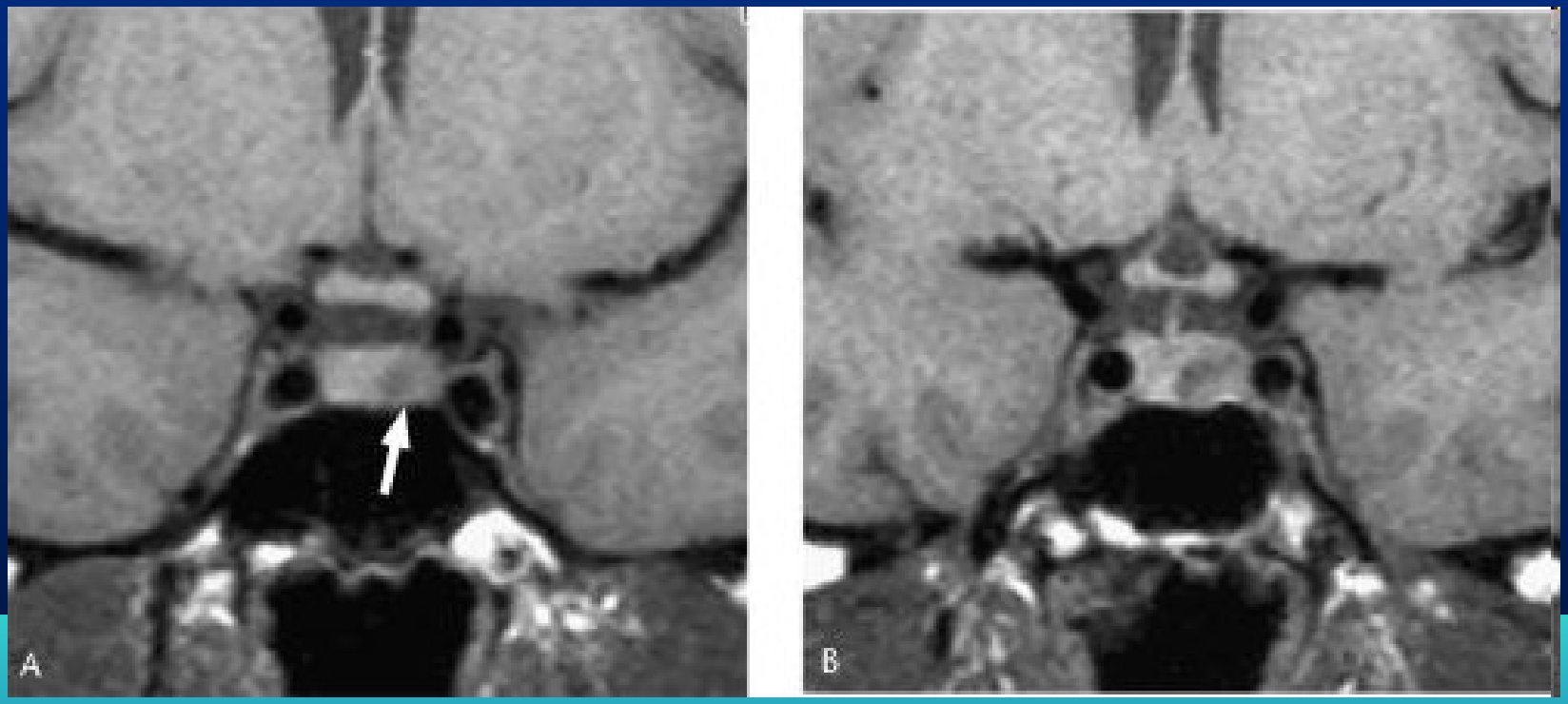

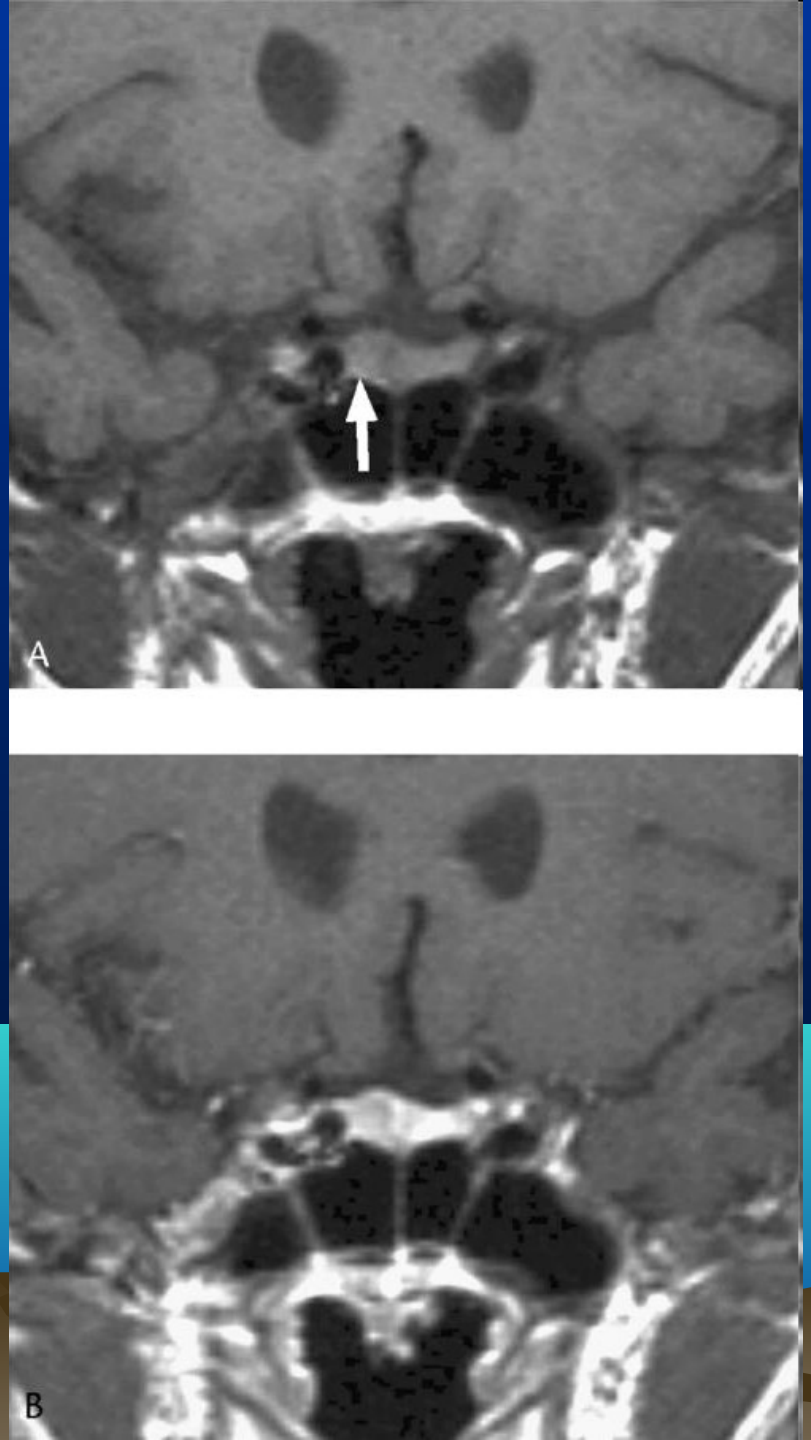

Tăng tín hiệu trên T1W

Tăng tín hiệu một phần trên T2W

Giảm tín hiệu trên T2W

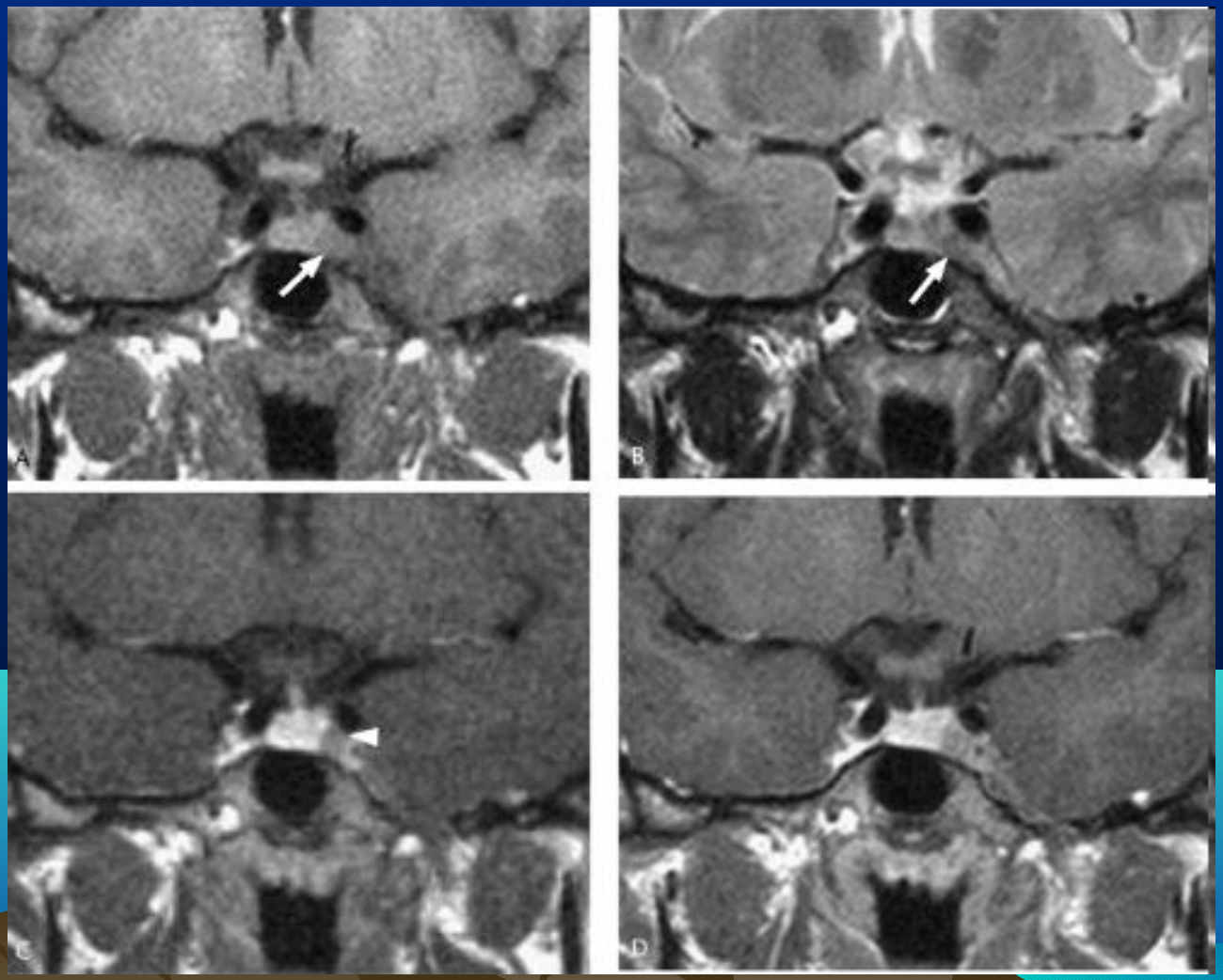

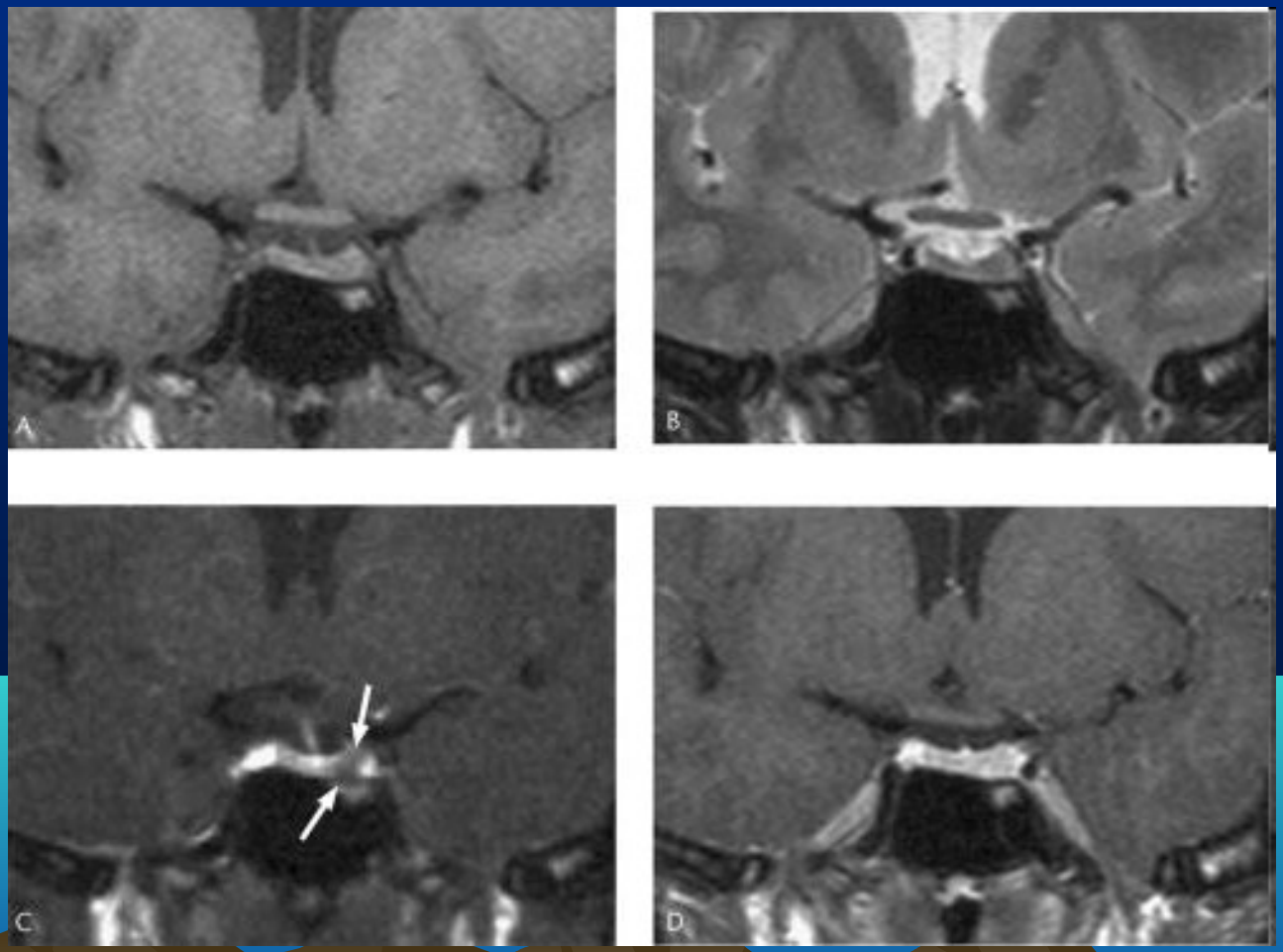
A
B
C
D

Microadenoma hình ảnh

- Độ nhạy toàn bộ của MRI để phát hiện microadenoma đến 90%

Dynamic CT

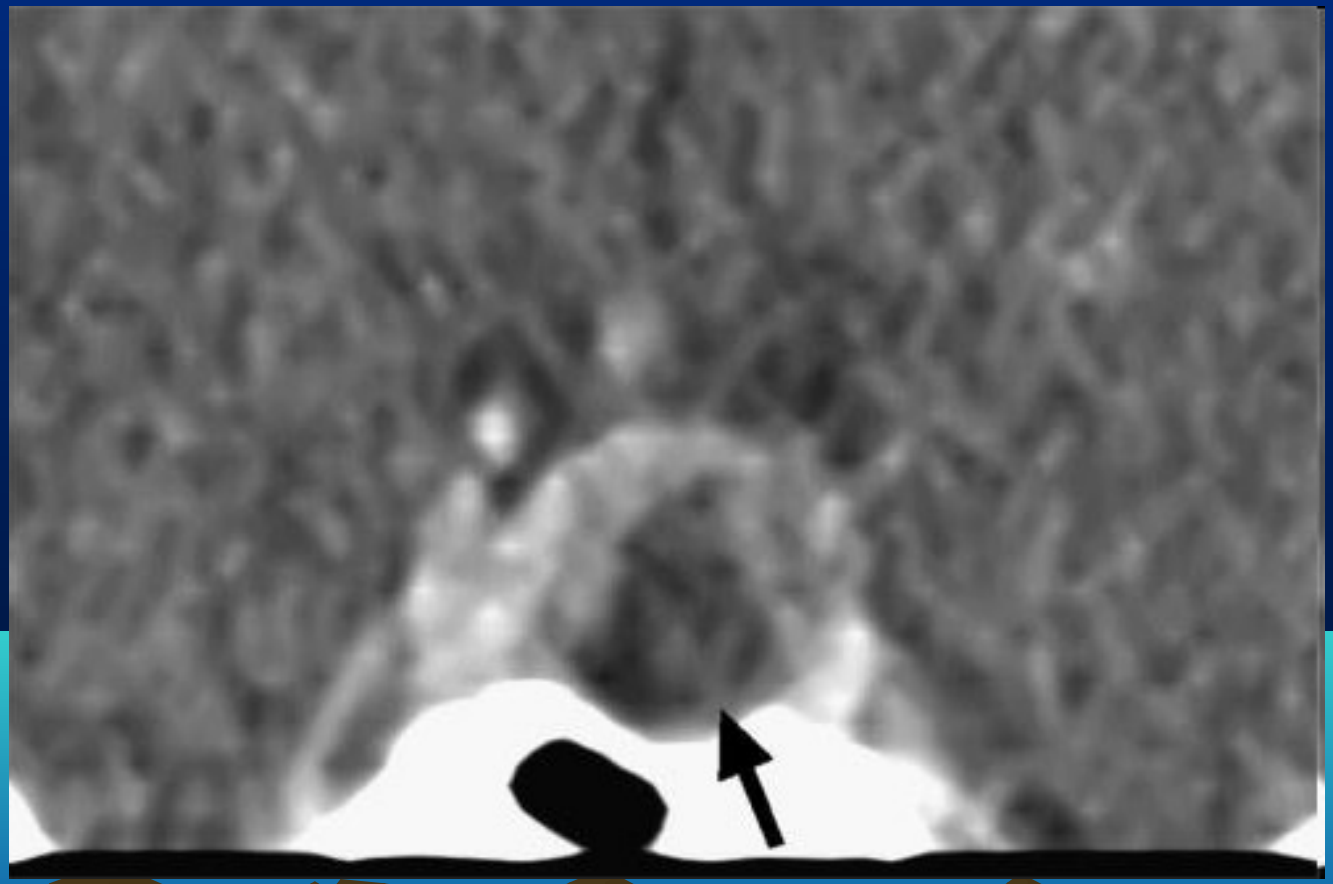

U tiết cortisol

- Bệnh Cushing
- Tổn thương rất nhỏ
- Độ nhạy của MRI 50-60%
- Lấy máu tĩnh mạch xoang hang và/hoặc xoang đá dưới

U xuất huyết

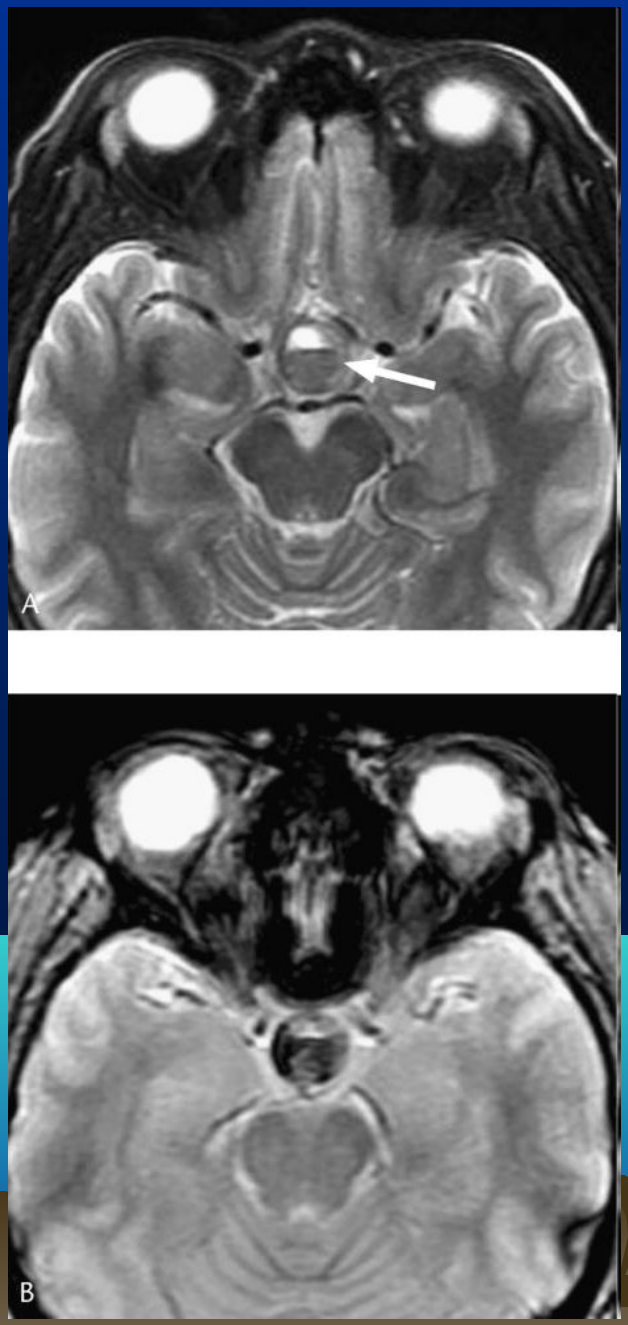

Bình thường!!!!

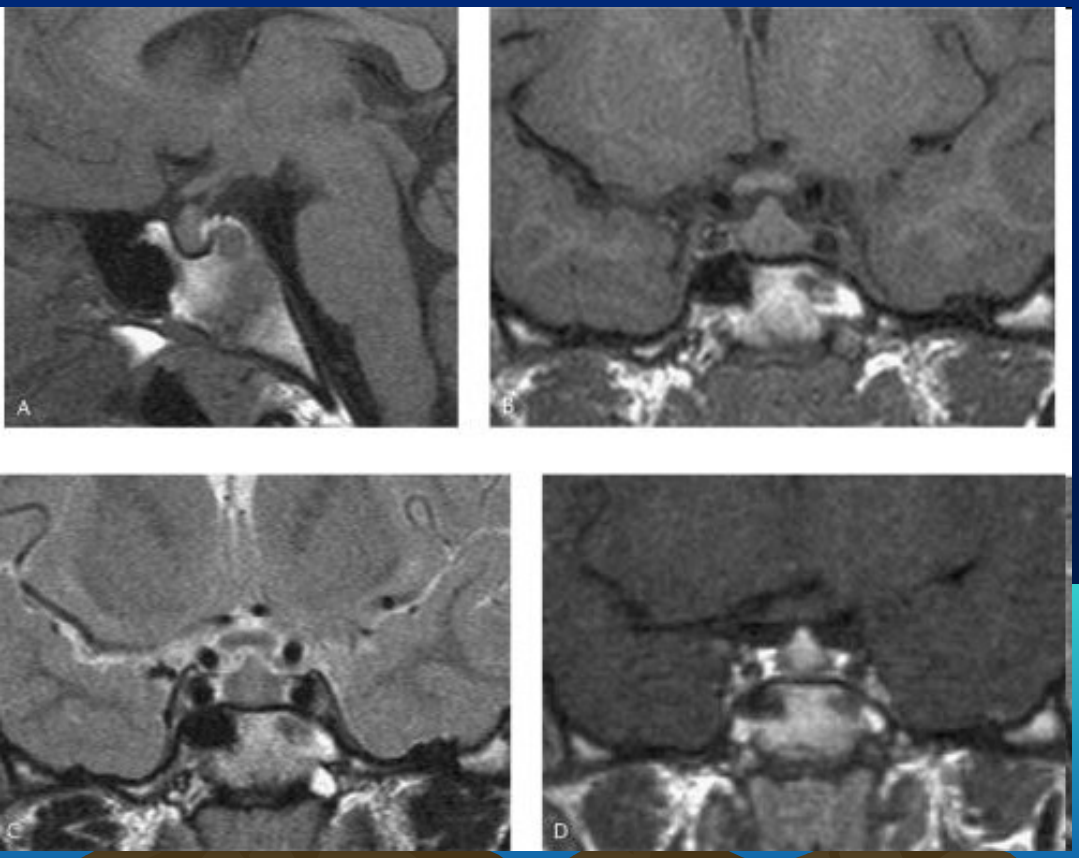

- Dậy thì, đặc biệt nữ
- Kinh nguyệt
- Có thai
- Tuần đầu sau sinh

Liều thuốc Gd cho dynamic tuyến yên

Neuroradiology (2006) 48: 449–459
DOI 10.1007/s00234-006-0085-0

DIAGNOSTIC NEURORADIOLOGY

Walter S. Bartynski
John F. Boardman
Stephen Z. Grahovac

The effect of MR contrast medium dose on pituitary gland enhancement, microlesion enhancement and pituitary gland-to-lesion contrast conspicuity

calculated in 18 patients receiving HD (0.05 mmol/kg), 9 receiving SD (0.1 mmol/kg) and 13 receiving DD (0.2 mmol/kg) contrast medium. Gland enhancement and microlesion enhancement over baseline were determined employing DICOM region of interest measurements and compared after normalization to tem-

ferences with larger contrast medium doses. *Conclusion:* Greater gland-to-lesion signal differences with larger contrast medium doses would likely improve pituitary microlesion visualization and margin characterization aiding in microlesion detection as well as preoperative planning.

Patricia C. Davis, MD • Kedar A. Gokhale, MD • Gregory J. Joseph, MD • Susan B. Peterman, MD
David A. Adams, PA • George T. Tindall, MD • Patricia A. Hudgins, MD • James C. Hoffman, Jr, MD

Pituitary Adenoma: Correlation of Half-Dose Gadolinium-enhanced MR Imaging with Surgical Findings in 26 Patients[1]

In this prospective study, visualization and localization of micro- and macroadenomas with surgical correlation by using a reduced dose of gadopentetate dimeglumine and MR imaging essentially equaled the accuracy of previously reported retrospective series that involved use of full-dose gadopentetate dimeglumine techniques. The benefits of this technique included lower cost of contrast material and lessened need for manipulation of window and level settings at the imaging console to detect small lesions. Although our correlation of surgical findings with MR imaging for microadenoma detection was excellent, careful clinical and endocrinologic follow-up of nonsurgical patients is required for both full- and half-dose sellar MR imaging techniques before accurate comparisons of sensitivity and specificity for adenoma detection can be determined. ■

Radiology 1991; 180:779-784
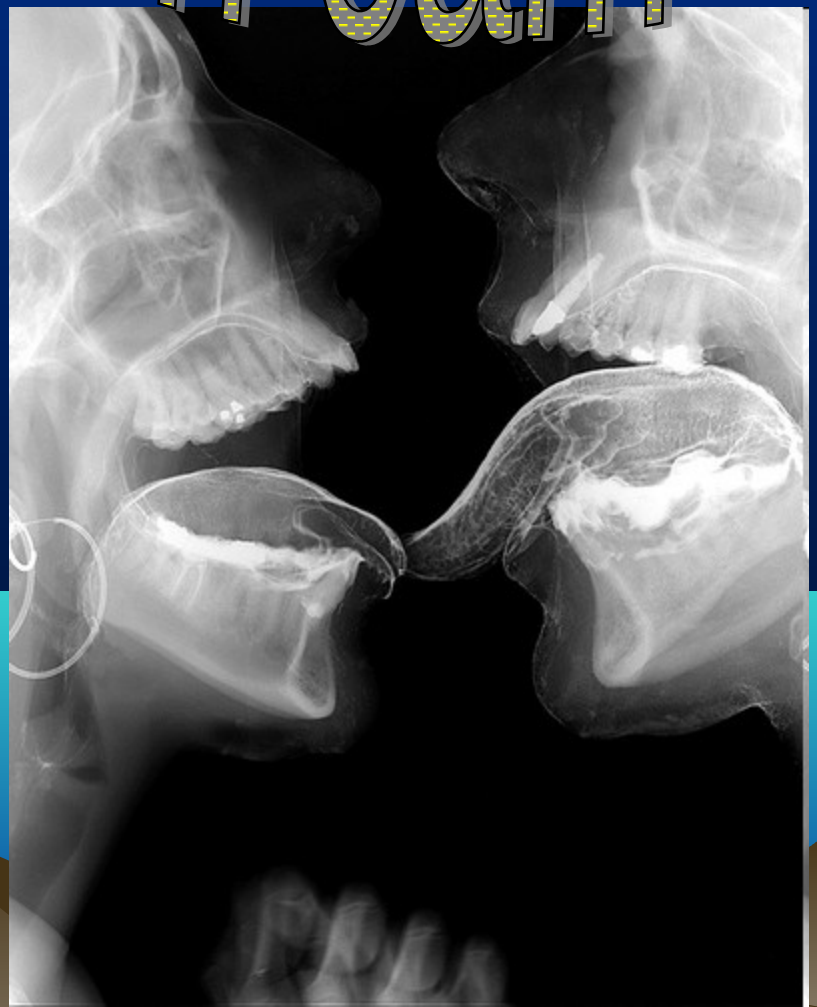
Xin cám ơn